

ANNALS 
of Internal Medicine

JULY 1979 • VOLUME 91 • NUMBER 1

Published Monthly by the American College of Physicians

The Chronic Sequelae of Non-A, Non-B Hepatitis

M. BERMAN, M.D.; H. J. ALTER, M.D.; K. G. ISHAK, M.D.; R. H. PURCELL, M.D.; and E. A. JONES, M.D.; Bethesda, Maryland; and Washington, D.C.

Twenty-six of 388 patients (6.7%) followed prospectively after open-heart surgery developed non-A, non-B hepatitis. Of these 26, 12 had an elevated (often fluctuating) serum alanine aminotransferase (SGPT) for greater than 1 year. Liver biopsy, done in eight of 12, showed chronic active hepatitis in six and chronic persistent hepatitis in two; one patient with chronic active hepatitis had early cirrhosis. Anicteric patients with peak SGPT greater than 300 IU/L were at greatest risk of developing chronic hepatitis. Chronic non-A, non-B hepatitis was symptomatically mild and unaccompanied by physical signs or laboratory evidence of autoimmune disease or severe chronic liver disease. In all 12 patients there was spontaneous improvement in serum transaminase over a period of 1 to 3 years, and four patients had sustained normalization of SGPT. Thus chronic active hepatitis is a common sequela of acute non-A, non-B hepatitis but may have a better prognosis than chronic active hepatitis of other causes.

WITH THE DEVELOPMENT of sensitive serologic markers for the hepatitis B surface antigen (HBsAg) (1) and for the hepatitis A antigen (2), two of the etiologic agents of viral hepatitis have been unequivocally identified. The existence of two serologically distinct hepatitis viruses confirms the findings of earlier human cross-challenge experiments by Krugman and associates (3). Subsequent data have suggested the existence of at least one additional human hepatitis virus, tentatively designated non-A, non-B (4). To date, no infectious particle has been reproducibly observed in association with non-A, non-B hepatitis, and no serologic marker has been defined. Nonetheless this putative agent(s) now accounts for 60% to 90% of post-transfusion hepatitis (5-9).

We describe here the chronic clinical and pathologic sequelae of non-A, non-B hepatitis identified in patients

► From the Liver Unit, National Institute of Arthritis, Metabolism, and Digestive Diseases; the Blood Bank Department, Clinical Center, and the Laboratory of Infectious Disease, National Institutes of Health, Bethesda, Maryland; and the Armed Forces Institute of Pathology, Washington, D.C.

prospectively followed after open-heart surgery.

Materials and Methods

Patients were hospitalized at the Clinical Center of the National Institutes of Health for corrective open-heart surgery and were followed prospectively for at least 9 months. Only patients older than 18 years with normal preoperative values for serum aspartic aminotransferase (SGOT) and alanine aminotransferase (SGPT) and negative tests for HBsAg were included in the study. Patients were excluded if they had received blood or plasma or had had other hepatitis exposure within the 6 months before cardiac surgery. Only volunteer donor blood, pre-screened for HBsAg by solid-phase radioimmunoassay (Ausria II; Abbott Laboratories, North Chicago, Illinois), was used.

Serum samples were obtained from patients weekly or bi-weekly during the first 3 months after transfusion, monthly for the next 3 months, and then again at 9 months after surgery. In cases of suspected hepatitis, weekly to biweekly serum samples were obtained until there was clear biochemical evidence of resolution or until transaminase elevations persisted beyond 4 months. In patients with these prolonged transaminase elevations and presumed chronic hepatitis, testing of serum samples was continued at 1- to 3-month intervals. Levels of SGPT, SGOT, and HBsAg were measured on all samples. Antibody to the hepatitis B surface (anti-HBs) and core (anti-HBc) antigens was tested by solid-phase radioimmunoassay (Ausab and Corab, respectively; Abbott Laboratories) on samples obtained pre-transfusion and at 3, 6, and 9 months post-transfusion. Acute and convalescent phase sera were obtained from patients with elevated serum transaminases and were tested for antibody responses to cytomegalovirus by complement fixation (10), Epstein-Barr virus by fluorescence microscopy (11), and hepatitis A virus by immune adherence hemagglutination (12).

Acute hepatitis was diagnosed when the SGPT exceeded 2.5 times the upper limit of laboratory normal between 2 and 26 weeks post-transfusion and when a repeat determination 1 week later was at least twice the upper limit of the normal range. Icteric hepatitis was diagnosed when the serum total bilirubin exceeded 2.5 mg/dL. Hepatitis was classified as type non-A, non-B if there was no serologic evidence of recent infection with hepatitis B virus, hepatitis A virus, Epstein Barr virus, or cytomegalovirus and if drugs and other known causes of elevated

Table 1. Histologic Findings and Diagnosis*

Patient	Time After Onset	Acidophilic Bodies	Ballooning of Hepatocytes	Focal Hepatocellular Necrosis	Erosion of Limiting Plates
	<i>mos.</i>				
1 First biopsy	12	2+	3+	0	0
Second biopsy	18	1+	1+	1+	1+
2	10	1+	1+	1+	0
3	8	1+	1+	2+	1+
4	10	2+	2+	1+	2+
5	7	2+	2+	2+	2+
6	10	2+	2+	2+	2+
7	17	1+	1+	1+	0
8	14	1+	2+	3+	3+

* 0 = absent; 1+ = minimal; 2+ = moderate; 3+ = marked.
 † L = lymphocyte; P = plasma cell; N = neutrophil; E = eosinophil.
 ‡ CPH = chronic persistent hepatitis; CAH = chronic active hepatitis.

serum transaminase could be reasonably excluded.

Patients were studied for the presence of chronic liver disease if serum transaminase values had not returned to normal within 6 months of their becoming elevated. Complete blood count, erythrocyte sedimentation rate, serum alkaline phosphatase, bilirubin, SGPT, SGOT, cholesterol, total protein, and protein electrophoresis were ascertained. Sera were also tested for the presence of antimitochondrial and antismooth muscle antibodies (in the laboratory of Dr. Willis Maddrey, Johns Hopkins School of Medicine, Baltimore, Maryland). If the SGPT remained elevated for greater than 6 months and there were no medical contraindications, aspiration needle biopsies of the liver were done in patients giving informed consent. All liver biopsy sections were stained by hematoxylin and eosin, Prussian blue, periodic acid-Schiff, Masson's trichrome, Manuel's reticulum, and the Shikata modification of the orcein stain for the demonstration of intracellular HBsAg (13). Biopsy slides were interpreted, under code, by one of the authors (KGI).

Results

CLINICAL DATA

Of the 388 consecutive patients satisfying admission criteria to the study and completing at least 6 months of follow-up, 30 (7.7%) developed acute hepatitis. Hepatitis B virus caused the hepatitis in three patients, and cytomegalovirus was considered to be the etiologic agent in one additional patient. Drug toxicity could not be specifically implicated, nor was there evidence in any patient of hypoxemia, sepsis, congestive heart failure, postpericardiotomy syndrome, or other clinical event that would implicate a nonviral cause for the elevated transaminase. The remaining 26 patients were classified as having acute non-A, non-B hepatitis. Twelve of these 26 patients had elevated serum transaminase levels for more than 1 year. Patients with chronic hypertransaminasemia did not differ appreciably from those with transient enzyme elevations in terms of mean age (46 versus 50 years), number of transfusions (16.0 ± 1.2 versus 18.2 ± 2.3), symptoms during the acute phase of their hepatitis, mean peak SGPT (729 versus 762 IU/L), range of SGPT (137 to 2322 versus 270 to 1600 IU/L), or the presence of icterus (five of 14 versus three of 12). Fifty percent of those with

acute hepatitis were men, while 75% of those who developed chronic hepatitis were men.

The mean incubation period, as measured to the first SGPT concentration to exceed 100 IU/L, in the 14 patients who recovered from their hepatitis was 7.5 weeks, with a range of 5 to 10 weeks. The mean incubation period among the 12 patients who developed chronic hepatitis was 9.1 weeks, with a range of 6 to 20 weeks. If the single patient with chronic hepatitis with a 20-week incubation period was excluded from analysis, then the mean incubation period in the chronic hepatitis group was 8.1 weeks and the range, 6 to 12 weeks. The mean incubation period of those whose hepatitis resolved did not differ significantly from those who developed chronic hepatitis ($t = 1.4$, $P > 0.1$ by Student's t test). In addition, there was marked overlap in the individual incubation periods among the patients in each of these groups.

There was no apparent association between the presence of icterus during the acute phase of hepatitis and the subsequent development of chronic liver disease; three of 12 patients who developed chronic liver disease were icteric, as compared with five of 14 who had transient hepatitis. Among anicteric patients, there was a statistically significant association between peak SGPT and the subsequent development of chronic hepatitis. Of nine anicteric patients whose peak SGPT was less than 300 IU/L, eight recovered completely. In contrast, of nine anicteric patients whose peak SGPT was greater than 300 IU/L, eight developed chronic hepatitis ($P < .005$ by chi-square analysis).

During a follow-up period of 3 to 40 months, 50% of the patients with persistent hypertransaminasemia experienced mild nonspecific constitutional symptoms, the most prominent of which was fatigue. None developed skin rash, arthritis, pruritis, or weight loss. None had cutaneous stigmata of chronic liver disease, and only one person (Patient 7, Table 1) had hepatomegaly; this patient also had tricuspid insufficiency, and the enlarged liver was pulsatile (see histologic data below). Erythro-

Table 1. (Continued)

Cholestasis	Chol- angiolar Prolifera- tion	Portal Inflammation†	Periportal Fibrosis	Diagnosis and Overall Degree of Activity‡	Patient
0	0	3+ (L, E, N)	0	Acute viral hepatitis in relapse	1 First biopsy
0	0	2+ (L, P, N, E)	0	CPH 1+	Second biopsy
0	0	2+ (L, P, N, E)	1+	CPH 1+	2
0	1+	3+ (L, P, E)	2+	CAH 2+	3
1+	2+	2+ (P, L)	2+	CAH 2+	4
0	0	3+ (L, P, N, E)	2+	CAH 2+	5
0	1+	3+ (L, P, N, E)	2+	CAH 2+	6
0	0	1+ (L, P)	3+	CAH 1+	7
0	1+	3+ (L, P, E)	3+	CAH 3+, early cirrhosis	8

cyte sedimentation rates of each patient remained within normal limits, and none of the patients exhibited anemia, leukopenia, or thrombocytopenia. All of the patients had normal cholesterol and serum albumin concentrations; only one patient had an elevated gamma globulin concentration (1.9 g/dL; upper limit of normal, 1.8 g/dL). Antimitochondrial antibodies were not detected in the serum of any patient, but antismooth muscle antibodies were present in two.

All of the patients were chronically receiving medications; these were begun either before or soon after surgery and did not differ from drugs received by patients who did not develop hepatitis or by patients whose hepatitis resolved spontaneously. There was no single medication taken by all 12 who developed chronic hepatitis. Aside from digoxin, taken by nine of the 12, no other single medication was taken by more than four patients. Furosemide, Coumadin, and aspirin were each taken by three patients and propranolol and diazepam by two. No other drug was administered to more than one of the 12 patients with chronic hepatitis.

DURATION OF ELEVATED SERUM TRANSAMINASE

Each of the 12 patients had serum transaminase measurements done for 10 to 46 months after values initially became elevated. In eight patients, the hypertransaminasemia was intermittent, often showing dramatic fluctuations over short time intervals. In some, transaminase values returned to normal only to be followed by distinct elevation in a subsequent sample. In no case was there evidence of cardiac decompensation, drug ingestion, or other apparent nonviral cause to account for the observed fluctuations in serum transaminase. Overall, there was a tendency for the SGPT to decline gradually over a period of 1 to 3 years in all patients (Figure 1). In four of the 12 patients, serum transaminase fell to within the normal range after being elevated for 13 to 32 months and subsequently remained normal in at least four consecutive serum samples spaced over an interval of 4 to 9 months. (Repeat biopsies are not available in these patients to ascertain if the biochemical resolution is accompanied by

histologic resolution.) In other patients, however, prolonged periods during which serum transaminase values were normal were followed by acute elevations of SGOT and SGPT.

HISTOLOGIC DATA

Seven of the 12 patients with persistent elevations of SGPT agreed to undergo a percutaneous needle liver biopsy. A wedge biopsy of the liver was obtained from one additional subject (Patient 4) at laparotomy for cholelithiasis. Patients were biopsied between 8 and 18 months after the onset of elevated serum transaminase.

The specific histologic abnormalities found in the eight patients are outlined in Table 1. To varying degrees, these changes were present in most patients: [1] hepatocellular unrest manifested by Kupffer cell hypertrophy and hyperplasia and by anisocytosis and anisonucleosis of hepatocytes; [2] unicellular hepatocytic degeneration in the form of ballooning or sinusoidal acidophilic bodies; [3] areas of focal necrosis with infiltration by mononuclear cells; [4] erosion of the limiting plate and entrapment of one or more hepatocytes by inflammatory cells; [5] a portal inflammatory cell infiltrate consisting primarily of lymphocytes and plasma cells, although eosinophils were also found in six cases; [6] periportal fibrosis; [7] absence of ground glass cells or cells positive for the Shikata orcein stain, and [8] absence of bridging necrosis. Some of the histologic features are shown in Figure 2.

The biopsies of two patients were classified as chronic persistent hepatitis, while the remaining six satisfied the histologic criteria for chronic active hepatitis (14, 15) (Table 1). In one subject (Patient 8), in whom the serum gamma globulin concentration was mildly elevated, there was histologic evidence of early cirrhosis. Patient 7, with clinical evidence of tricuspid insufficiency, had both passive congestion and chronic active hepatitis in her liver biopsy.

Discussion

A decade ago, the cause of most cases of chronic active hepatitis was highly speculative and was considered to be

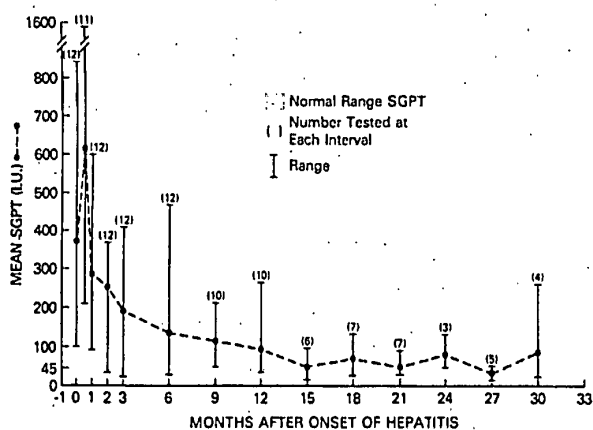


Figure 1. The mean and range of serum glutamic pyruvic transaminase (SGPT) in 12 patients with chronic hepatitis followed over an interval of 30 months.

almost solely due to autoimmune processes (16, 17). The etiologic spectrum of chronic active hepatitis has subsequently been extended and better defined. Congenital diseases such as Wilson's disease (18, 19) and alpha₁-antitrypsin deficiency (20) and toxicity due to medications such as oxyphenisatin (21), methyldopa (22), and isoniazid (23) exemplify the multiple causes of this histologic lesion. In addition, it has become apparent that viral hepatitis plays a major role in the development of some cases of chronic active hepatitis. The hepatitis B virus has been clearly implicated in the development of chronic liver disease. Not only do many patients with chronic liver disease have HBsAg in their serum (24), but histologic progression from acute type B hepatitis to either chronic persistent or chronic active hepatitis has been well documented (25). Interestingly, the type A hepatitis virus has not been associated with the development of chronic liver disease (26). Recent studies in patients receiving blood transfusions have provided strong evidence for the existence of at least one additional human hepatitis virus, serologically distinct from the type A and type B viruses and tentatively designated "non-A, non-B." This agent(s) accounts for 60% to 90% of post-transfusion hepatitis (5-9) and an unknown proportion of hepatitis cases occurring without prior transfusion (27). As shown in our study and in a study by Knodell and associates (28), acute non-A, non-B hepatitis frequently progresses to chronic liver disease; indeed, acute icteric or anicteric non-A, non-B hepatitis may be one of the major predisposing factors in the development of chronic active hepatitis.

Several interesting features of non-A, non-B hepatitis and its relation to chronic liver disease derive from this study. First, although it can be clinically severe, acute non-A, non-B hepatitis after transfusion is usually an anicteric, mildly symptomatic disease and probably goes undetected in most patients not prospectively followed. A very large number of non-A, non-B hepatitis cases may occur each year, but an accurate assessment of its incidence will not be possible until tests are developed that will detect specific serologic markers.

Second, many cases of non-A, non-B hepatitis are associated with prolonged elevations of serum transaminase. In our study, 46% of patients with acute non-A, non-B hepatitis had an elevated SGPT for greater than 1 year after onset of their disease. In a similar prospective study by Knodell and co-workers (28), 23% of patients with acute non-A, non-B hepatitis had evidence of chronic liver dysfunction.

Third, the predominant histologic lesion of chronic non-A, non-B hepatitis appears to be chronic active hepatitis; six of eight patients who underwent liver biopsy in this study had chronic active hepatitis, as did eight of 10 in the study by Knodell and colleagues (28). In combination, these first three points indicate that the agent(s) responsible for non-A, non-B hepatitis results in a disease frequently unrecognized in its initial stages but which nonetheless often leads to chronic liver disease, most commonly chronic active hepatitis. Since there is currently no serologic marker for non-A, non-B hepatitis, it is impossible to ascertain at this time the number of cases of chronic active hepatitis etiologically related to this agent(s). The implication is, however, that non-A, non-B hepatitis may account for a major portion of chronic active hepatitis that cannot otherwise be attributed to drug toxicity or autoimmune phenomena.

Fourth, among patients with acute, anicteric non-A, non-B hepatitis in this study, the tendency to develop chronic hepatitis could be predicted by the peak SGPT elevation; anicteric patients with an SGPT in excess of 300 IU/L were much more likely to develop chronic liver disease than were those with lesser elevations. Although this difference was highly significant, a much larger number of cases will have to be followed to verify this observation. There was no statistical association between the peak SGPT level and the tendency to progress to chronic liver disease among patients with icteric, non-A, non-B hepatitis. Progression to chronic liver disease was independent of age, the number of transfusions, or the magnitude of clinical signs and symptoms. Similarly, there was no significant association between the incubation period, as measured to the first SGPT to exceed 100 IU/L, and the subsequent development of chronic hepatitis. Except for one patient with an incubation period of 20 weeks, the incubation periods had a unimodal distribution, with all cases occurring between 5 and 12 weeks after transfusion. While not excluding such a possibility, the observed incubation periods did not suggest the existence of more than one non-A, non-B agent or that patients with "short incubation" non-A, non-B hepatitis were more or less likely to develop chronic liver disease than were patients with "long incubation" non-A, non-B hepatitis.

Fifth, although one of our patients with chronic non-A, non-B hepatitis and one in a previous study (6) had histologic evidence of cirrhosis, patients with non-A, non-B hepatitis, including those with chronic active hepatitis, usually show gradual improvement in abnormal serum biochemical indices. In four of our 12 cases, there appears to have been a complete serum biochemical resolution of the disease. Koretz and Gitnick (29) have reported that SGPT levels returned to normal in 13 of 23

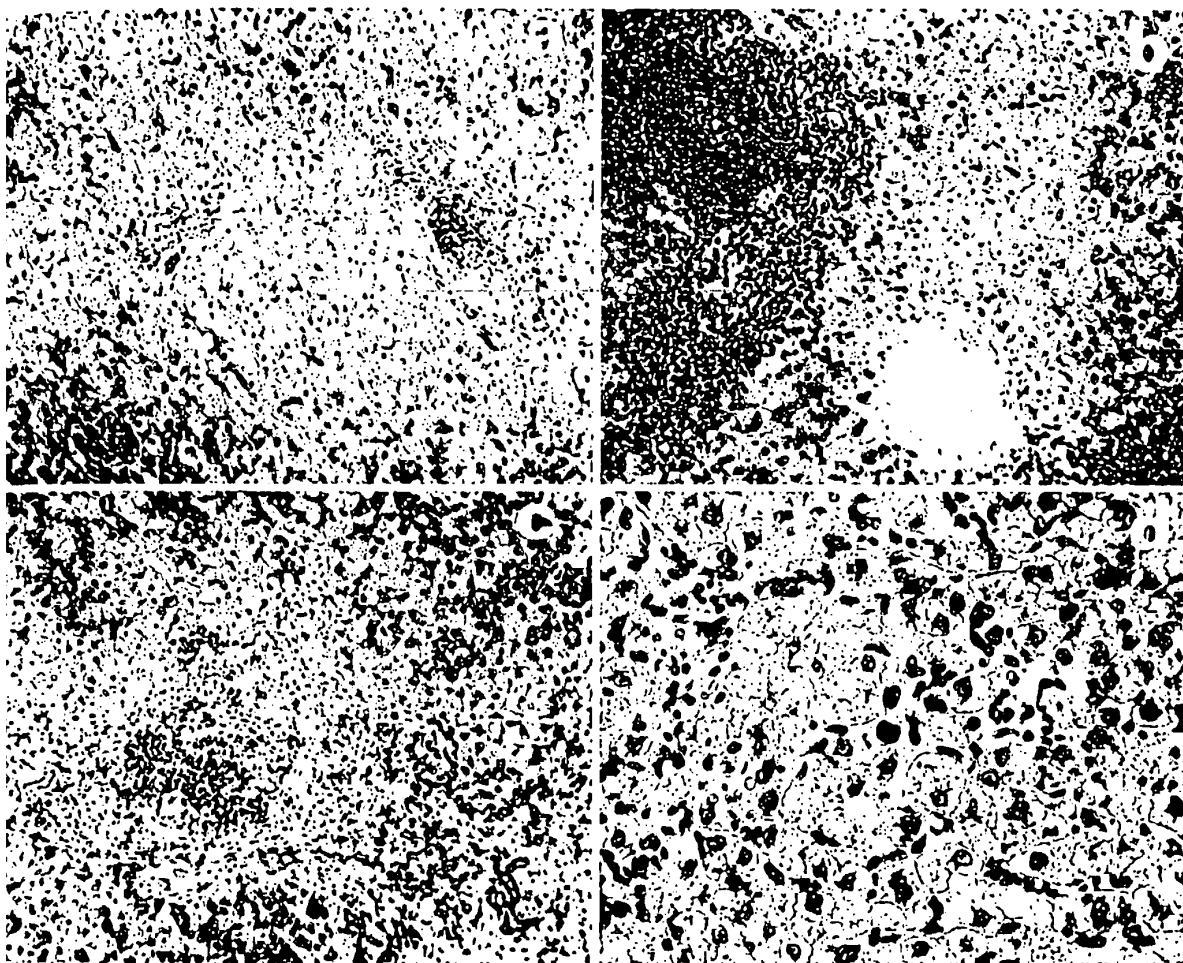


Figure 2a. Patient 2. Chronic persistent hepatitis. Two portal areas are sharply defined and contain a mild infiltrate of mononuclear cells. (Hematoxylin and eosin; original magnification, $\times 160$. Armed Forces Institute of Pathology [AFIP] 78-3523.) b. Patient 3. Chronic active hepatitis. Expanded portal area (*left*) is poorly demarcated from the adjacent parenchyma and is heavily infiltrated with mononuclear cells. (Hematoxylin and eosin; original magnification, $\times 160$. AFIP 78-9804.) c. Patient 8. Chronic active hepatitis. Two adjacent portal areas are inked together by fibrous tissue and a moderate inflammatory infiltrate. (Hematoxylin and eosin; original magnification, $\times 160$. AFIP 78-2589.) d. Patient 8. Chronic active hepatitis. Hepatocytes show moderate anisocytosis, anisonucleosis, and ballooning. A round sinusoidal acidophilic body is seen in the center. (Hematoxylin and eosin; original magnification, $\times 400$. AFIP 78-2597.)

patients with chronic liver disease acquired after blood transfusion. Normalization of serum transaminase levels does not, however, necessarily exclude histologically active chronic hepatitis (30). Consequently, repeat liver biopsies are needed to evaluate adequately the hepatitis status of patients who have had serum biochemical resolution. Although biopsy findings in most of these patients are consistent with the histologic definition of chronic active hepatitis (14, 15), the absence of bridging necrosis or active cirrhosis, the generally mild transaminase abnormalities that tended to resolve, and the absence of clinical sequelae of chronic liver disease all suggest that the chronic active hepatitis following non-A, non-B post-transfusion hepatitis may be slowly resolving rather than chronically progressing and may not forebode the poor prognosis (31, 32) generally attributed to this histologic classification.

Finally, only one of the patients in our study was treat-

ed with corticosteroids or other immunosuppressive drugs. There was no difference in the clinical or serum biochemical pattern of disease between this patient and others who did not receive corticosteroids. In view of the generally asymptomatic nature of this disease and of the trend toward spontaneous biochemical resolution, it would be difficult to evaluate the efficacy of drug therapy. A large, controlled, prospective study is needed to ascertain whether corticosteroids are indicated in the treatment of chronic non-A, non-B hepatitis (33, 34).

Studies in chimpanzees (35, 36) have found a transmissible agent in the serum of patients with both acute and chronic non-A, non-B hepatitis. This agent(s) is presumably a virus, but its viral nature has not been proved. A viruslike particle has been reported in the liver of a chimpanzee with acute non-A, non-B hepatitis (37), but this observation has not been confirmed. Similarly, there has been no verified serologic test for a non-A, non-B hepati-

tis agent. The development of a reliable serologic test for the non-A, non-B agent(s) will not only have a major impact on the prevention of hepatitis after transfusion but will define the extent to which non-A, non-B viral infection is a cause of chronic active hepatitis, chronic persistent hepatitis, and cirrhosis.

► Requests for reprints should be addressed to Harvey J. Alter, M.D.; Blood Bank Department, Building 10A, Room 1E33, National Institutes of Health, 9000 Rockville Pike; Bethesda, MD 20014.

Received 9 October 1978; revision accepted 15 February 1979.

References

- BLUMBERG BS, ALTER HJ, VISNICK S. A new antigen in leukemic sera. *JAMA*. 1965; 191:541-6.
- FEINSTONE SM, KAPKIAN AZ, PURCELL RH. Hepatitis A: detection by immune electron microscopy of a viruslike antigen associated with acute illness. *Science*. 1973; 182:1026-8.
- KRUGMAN S, GILES JP, HAMMOND J. Infectious hepatitis: evidence for two distinctive clinical, epidemiological and immunological types of infection. *JAMA*. 1967; 200:365-73.
- PURCELL RH, ALTER HJ, DIENSTAG JL. Non-A, non-B Hepatitis. *Yale J Biol Med*. 1976; 49:243-50.
- PRINCE AM, BROTMAN B, GRADY GF, et al. Long-incubation post-transfusion hepatitis without serological evidence of exposure to hepatitis-B virus. *Lancet*. 1974; 2:241-6.
- ALTER HJ, PURCELL RH, HOLLAND PV, FEINSTONE SM, MORROW AG, MORITSUGU Y. Clinical and serological analysis of transfusion-associated hepatitis. *Lancet*. 1975; 2:838-41.
- AACH RD, LANDER JJ, SHERMAN LA, et al. Transfusion-transmitted viruses: interim analysis of hepatitis among transfused and nontransfused patients. In: VYAS GN, COHEN SN, SCHMID R, eds. *Viral Hepatitis*. Philadelphia: Franklin Institute Press; 1978:383-96.
- SEEFF LB, ZIMMERMAN HJ, WRIGHT EC, et al. A randomized, double blind controlled trial of the efficacy of immune serum globulin for the prevention of post-transfusion hepatitis. *Gastroenterology*. 1977; 72:111-21.
- KNOBELL RG, CONRAD ME, GINSBERG AL, BELL CJ. Efficacy of prophylactic gamma-globulin in preventing non-A, non-B post-transfusion hepatitis. *Lancet*. 1976; 1:557-61.
- PURCELL RH, WALSH JH, HOLLAND PV, MORROW AG, WOOD S, CHANOCK RM. Seroepidemiological studies of transfusion-associated hepatitis. *J Infect Dis*. 1971; 123:406-13.
- HENLE G, HENLE W. Immunofluorescence in cells derived from Burkitt's lymphoma. *J Bacteriol*. 1966; 91:1248-56.
- MORITSUGU Y, DIENSTAG JL, VALDESUSO J, et al. Purification of hepatitis A antigen from feces and detection of antigen and antibody by immune adherence hemagglutination. *Infect Immun*. 1976; 13:898-908.
- SHIKATA T, UZAWA T, YOSHIWARA N, AKATSUKA T, YAMASAKI S. Staining methods of Australia antigen in paraffin section: detection of cytoplasmic inclusion bodies. *Jpn J Exp Med*. 1974; 44:25-35.
- ISHAK KG. Light microscopic morphology of viral hepatitis. *Am J Clin Pathol*. 1976; 65:787-827.
- SCHUEER PJ, THALER H. Acute and chronic hepatitis revisited: review by an International Group. *Lancet*. 1977; 2:914-9.
- GEALL MG, SCHOENFIELD MD, SUMMERSKILL DM. Classification and treatment of chronic active hepatitis. *Gastroenterology*. 1968; 55:724-9.
- MISTILIS SP, BLACKBURN CRB. Active chronic hepatitis. *Am J Med*. 1970; 48:484-95.
- STERNLIEB I, SCHEINBERG IH. Chronic hepatitis as a first manifestation of Wilson's disease. *Ann Intern Med*. 1972; 76:59-64.
- SCOTT J, GOLLAN JL, SAMOURIAN S, SHERLOCK S. Wilson's disease, presenting as chronic active hepatitis. *Gastroenterology*. 1978; 74:643-51.
- TRIGER DR, MILLWARD-SADLER GH, CZAYKOWSKI AA, TROWELL J, WRIGHT R. Alpha-1-antitrypsin deficiency and liver disease in adults. *Q J Med*. 1976; 45:351-72.
- REYNOLDS TB, PETERS RL, YAMADA S. Chronic active and lupoid hepatitis caused by a laxative, oxyphenisatin. *N Engl J Med*. 1971; 285:813-20.
- TOGHILL PJ, SMITH PG, DENTON P, BROWN RC, MATTHEWS HL. Methylodopa liver damage. *Dr Med J*. 1974; 3:545-8.
- BLACK M, MITCHELL JR, ZIMMERMAN HJ, ISHAK KG, EPLER GR. Isoniazid-associated hepatitis in 114 patients. *Gastroenterology*. 1975; 69:289-302.
- WRIGHT R, MCCOLLUM RW, KLATSKIN G. Australia antigen in acute and chronic liver disease. *Lancet*. 1969; 2:117-21.
- REDEKER AG. Chronic viral hepatitis. In: VYAS GN, PERKINS HA, SCHMID R, eds. *Hepatitis and Blood Transfusion*. New York: Grune and Stratton; 1972:55-60.
- RAKELA J, REDEKER AG, EDWARDS VM, DECKER R, OVERBY LR, MOSLEY JW. Hepatitis A virus infection in fulminant hepatitis and chronic active hepatitis. *Gastroenterology*. 1978; 74:879-82.
- DIENSTAG JL, ALAAMA A, MOSLEY JW, REDEKER AG, PURCELL RH. Etiology of sporadic hepatitis B surface antigen-negative hepatitis. *Ann Intern Med*. 1977; 87:1-6.
- KNOBELL RG, CONRAD ME, ISHAK KG. Development of chronic liver disease after acute non-A, non-B post-transfusion hepatitis: role of r-globulin prophylaxis in its prevention. *Gastroenterology*. 1977; 72:902-9.
- KORETZ RL, GITNICK GL. The long term course of chronic post-transfusion hepatitis. *Gastroenterology*. 1978; 74:1050. Abstract.
- BOLIN TD, DAVIS AE, LIDDELOW AG. Liver disease and cell-mediated immunity in hepatitis-associated antigen (HAA) carriers. *Gut*. 1973; 14:365-8.
- COOK GC, MULLIGAN R, SHERLOCK S. Controlled prospective trial of corticosteroid therapy in active chronic hepatitis. *Q J Med*. 1971; 40:159-85.
- SOLOWAY RD, SUMMERSKILL WHJ, BAGGENSTOSS AH, et al. Clinical biochemical and histological remission of severe chronic active liver disease: a controlled study of treatment and early prognosis. *Gastroenterology*. 1972; 63:820-33.
- BERK PD, JONES EA, PLOTZ PH, SEEFF LB, WRIGHT EC. Corticosteroid therapy for chronic active hepatitis. *Ann Intern Med*. 1976; 85:523-5. Editorial.
- WRIGHT EC, SEEFF LB, BERK PD, JONES EA, PLOTZ PH. Treatment of chronic active hepatitis: an analysis of three controlled trials. *Gastroenterology*. 1977; 73:1422-30.
- ALTER HJ, PURCELL RH, HOLLAND PV, POPPER H. Evidence for a transmissible agent in non-A, non-B hepatitis. *Lancet*. 1978; 1:459-63.
- TABOR E, GERETY RJ, DRUCKER JA, et al. Transmission of non-A, non-B hepatitis from man to chimpanzee. *Lancet*. 1978; 1:463-5.
- CENTER FOR DISEASE CONTROL. Recovery of virus-like particles associated with non-A, non-B hepatitis. *Morbid Mortal Weekly Rep*. 1978; 27:199-200.